

HEALTH MAINTENANCE IN SPINAL CORD INJURY

Anthony Chiodo, MD, MBA

Michigan Medicine

- ▶ Emphasis on neurological assessment and impact on functional outcome
- ▶ Emphasis on interventions to improve functional outcome: rehabilitation therapies, tendon/nerve transfers, late complications impacting function, secondary conditions, equipment and modifications
- ▶ However, there is a large body of research regarding the physiological changes after SCI and their impact on aging and health risk
- ▶ It is this aspect of SCI medicine that we will explore today

SCI MEDICINE MORE THAN FUNCTION

- ▶ Recent hospitalizations, infections or new medical diagnoses that have been made since last visit
- ▶ New problems or changes in existing medical problems
- ▶ Changes in function or activities of daily living
- ▶ Updates in medications and allergies
- ▶ A review of symptoms/systems
- ▶ Changes in mood, relationships or employment status
- ▶ Changes in tobacco, alcohol or drug use
- ▶ Updates of family medical problems
- ▶ A physical examination

ANNUAL EVALUATION BY AN SCI MEDICINE SPECIALIST

- ▶ Skin examination
- ▶ Gynecological and breast cancer screening
- ▶ Colon cancer screening

UNCHANGED HEALTH MAINTENANCE

A decorative graphic consisting of several parallel white lines of varying lengths, slanted upwards from left to right, located in the bottom right corner of the slide.

- ▶ Peripheral
 - ▶ Carpal tunnel syndrome
 - ▶ Ulnar neuropathy
- ▶ Cervical and Thoracic
 - ▶ Cervical spondylosis myelopathy
 - ▶ Radiculopathy due to spondylosis
 - ▶ Syrinx
- ▶ Lumbar
 - ▶ Lumbar epidural fibrosis
 - ▶ Lumbar stenosis

CHANGES IN NEUROLOGICAL FUNCTION

- ▶ 37 year old T11 ASIA A Spinal Cord injury
 - ▶ Bilateral hand numbness
 - ▶ Worse at night and first thing in the morning
 - ▶ Worse with hand cycling
 - ▶ Left lower abdominal pain and left leg spasticity
 - ▶ Worse with prolonged sitting
 - ▶ Improved with time in the standing frame

CASES

- ▶ 55 year old with old thoracic disc herniation and myelopathy with progressive lower extremity spasticity and weakness. Baseline examination with pin level at T6, intact vibration sense, 3+ reflexes without clonus nor spasticity, 5/5 strength.

Lower extremity reflexes are 3+ with sustained left ankle clonus and bilateral extensor plantar responses.

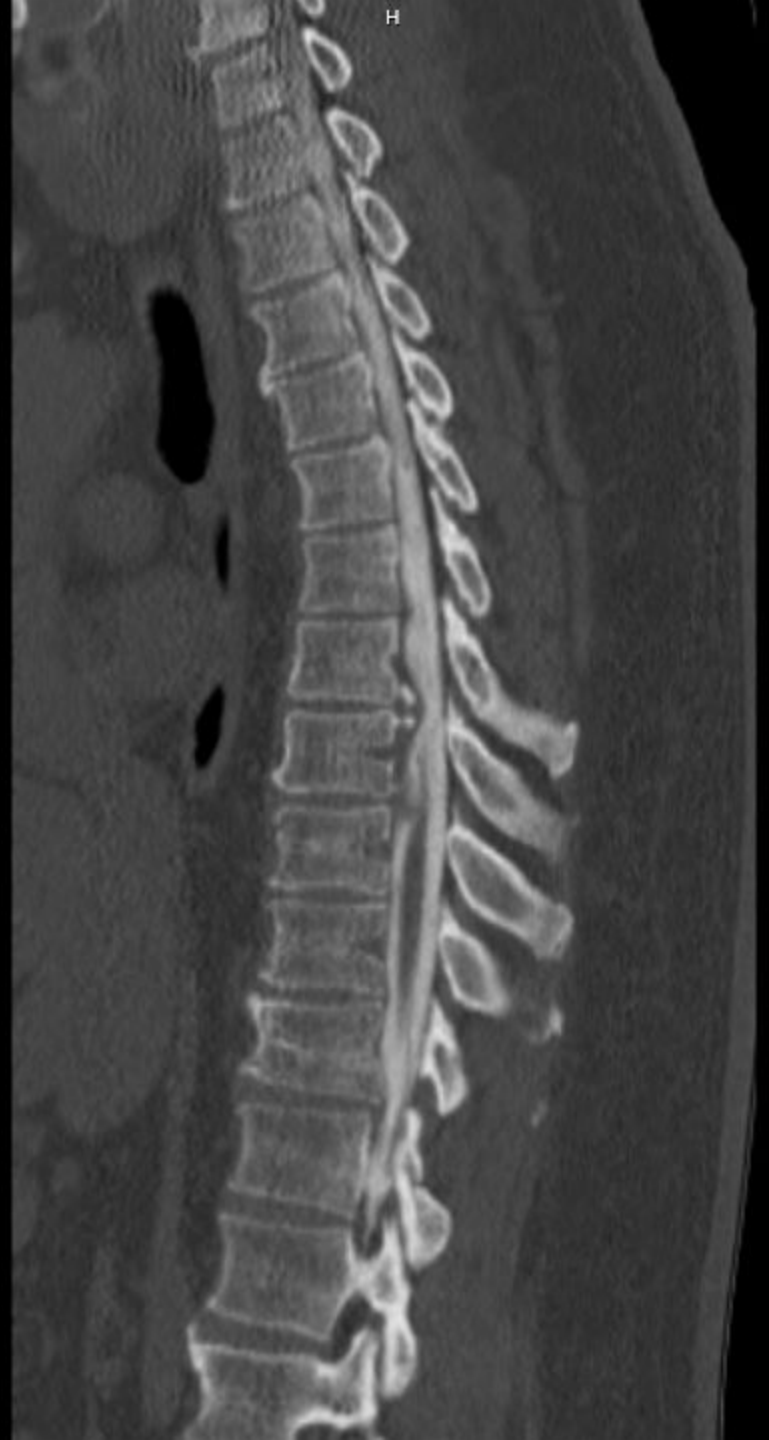Ashworth scores are 1+ at the hips bilaterally, 2 at the quadriceps, 1 at the hamstring and right ankle, 1+ at the left ankle.

Pin sensation is a T6 pin level bilaterally with patchy decreased pin sensation in the right lower abdomen, markedly decreased pin sensation below the knee on the right leg compared to the left with intact vibration sense bilaterally.

Strength is 4+ right lower extremity, 4 to 4- on the left.

038556459
M 14-Apr-59
05-Mar-15 12:50:25 PM
5342

120 kV ? mA



A

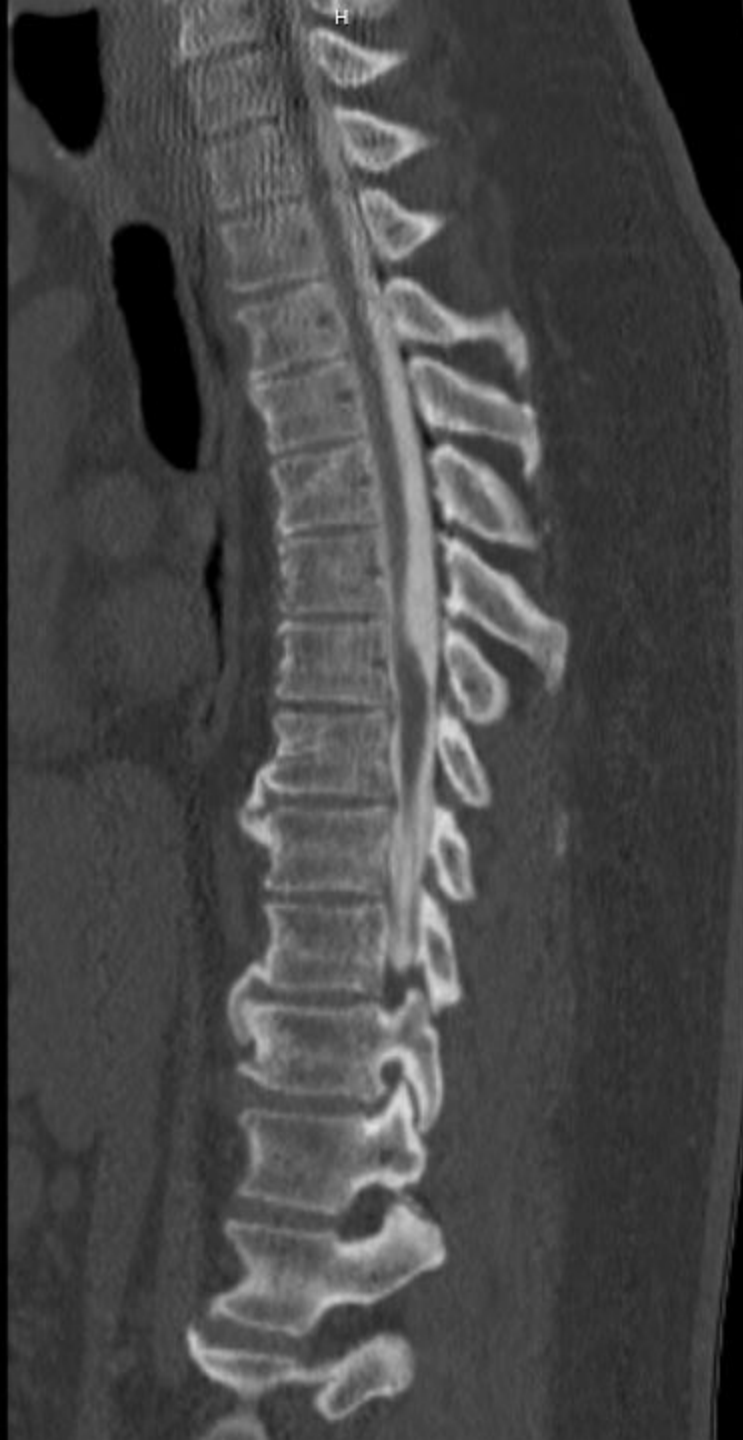

SPINE 2 q 2
CT1

FOV: 407
512x512
2 @ -11 503231

038556459
M 14-Apr-59
05-Mar-15 12:50:25 PM
5342

120 kV ? mA



A

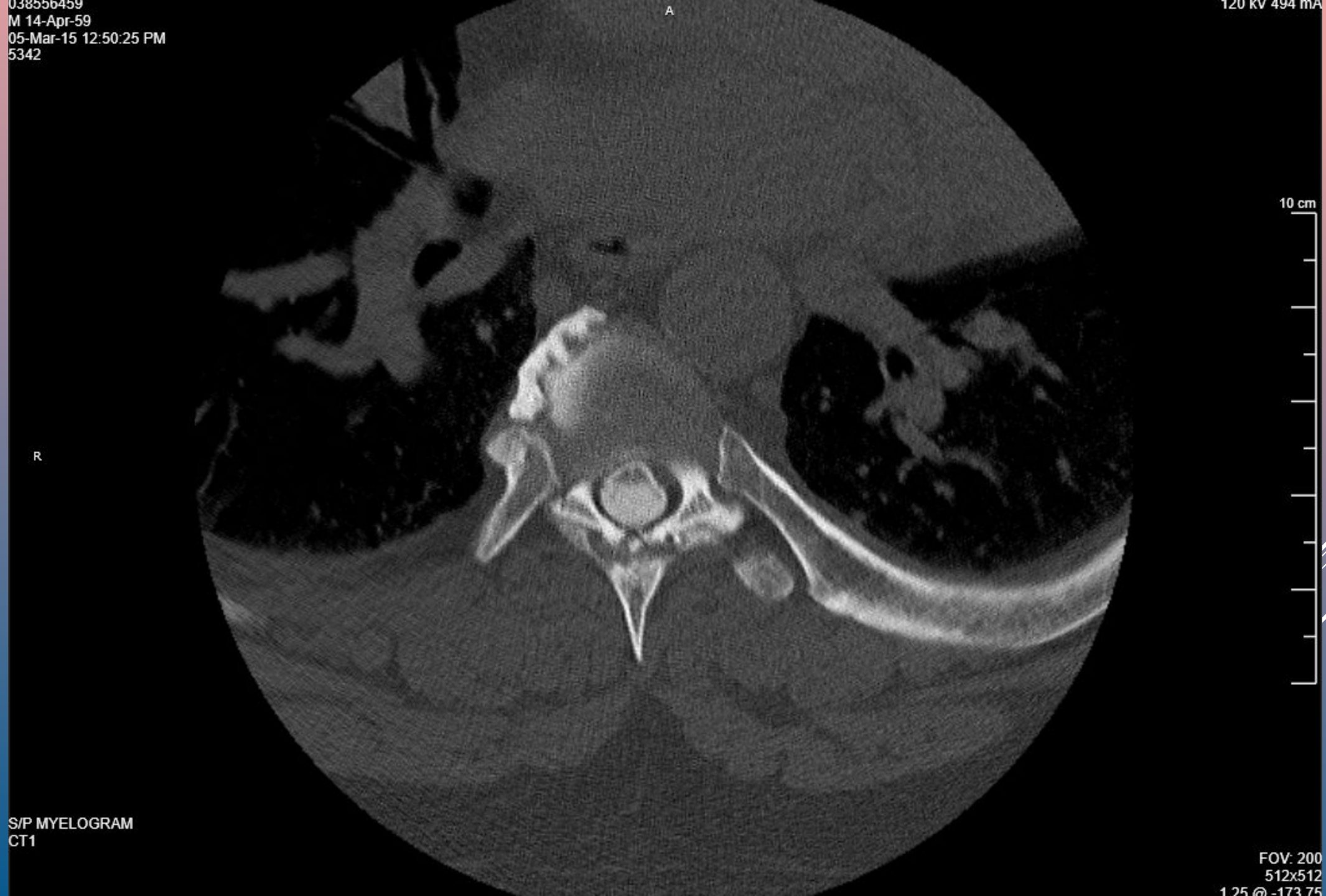


SPINE 2 q 2
CT1

FOV: 407
512x512
2 @ -5 512924

038556459
M 14-Apr-59
05-Mar-15 12:50:25 PM
5342

120 kV 494 mA



R

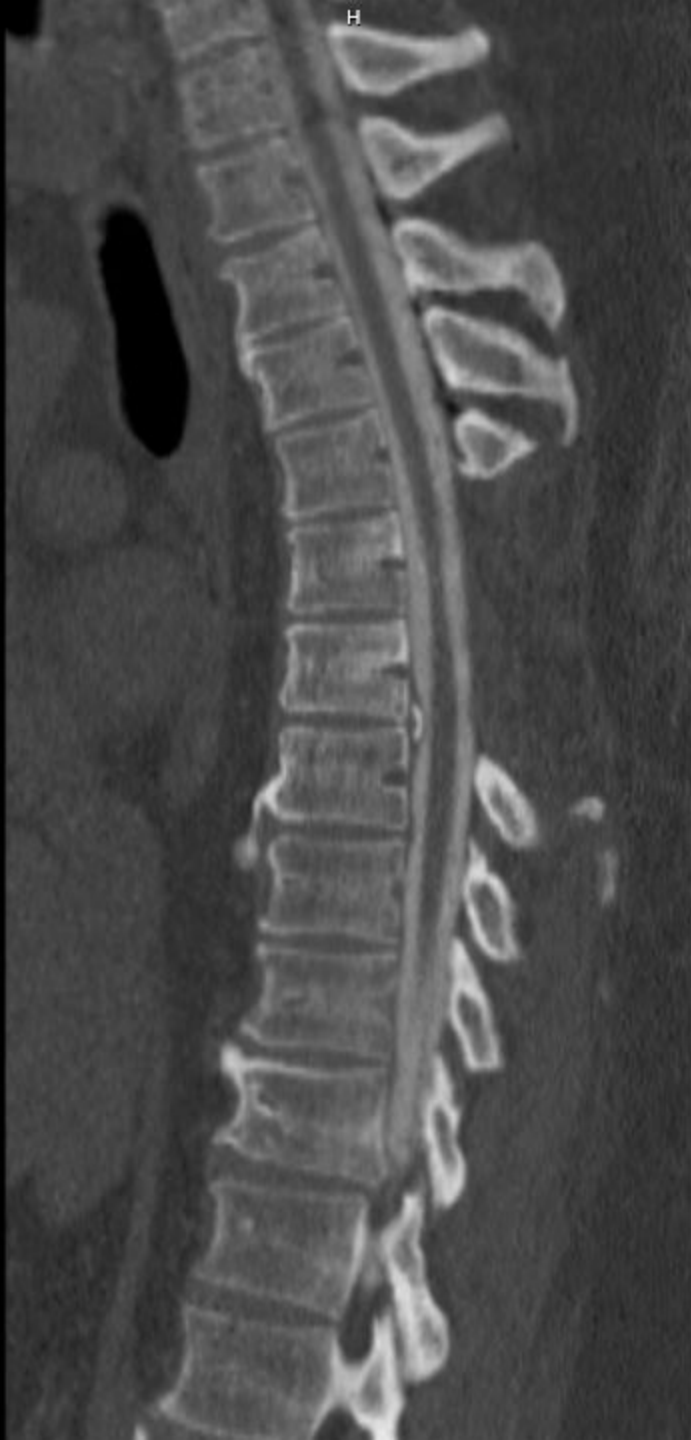

S/P MYELOGRAM
CT1

FOV: 200
512x512
1.25 @ -173.75

038556459
M 14-Apr-59
16-May-17 10:22:48 AM
13675

120 KV 468 mA

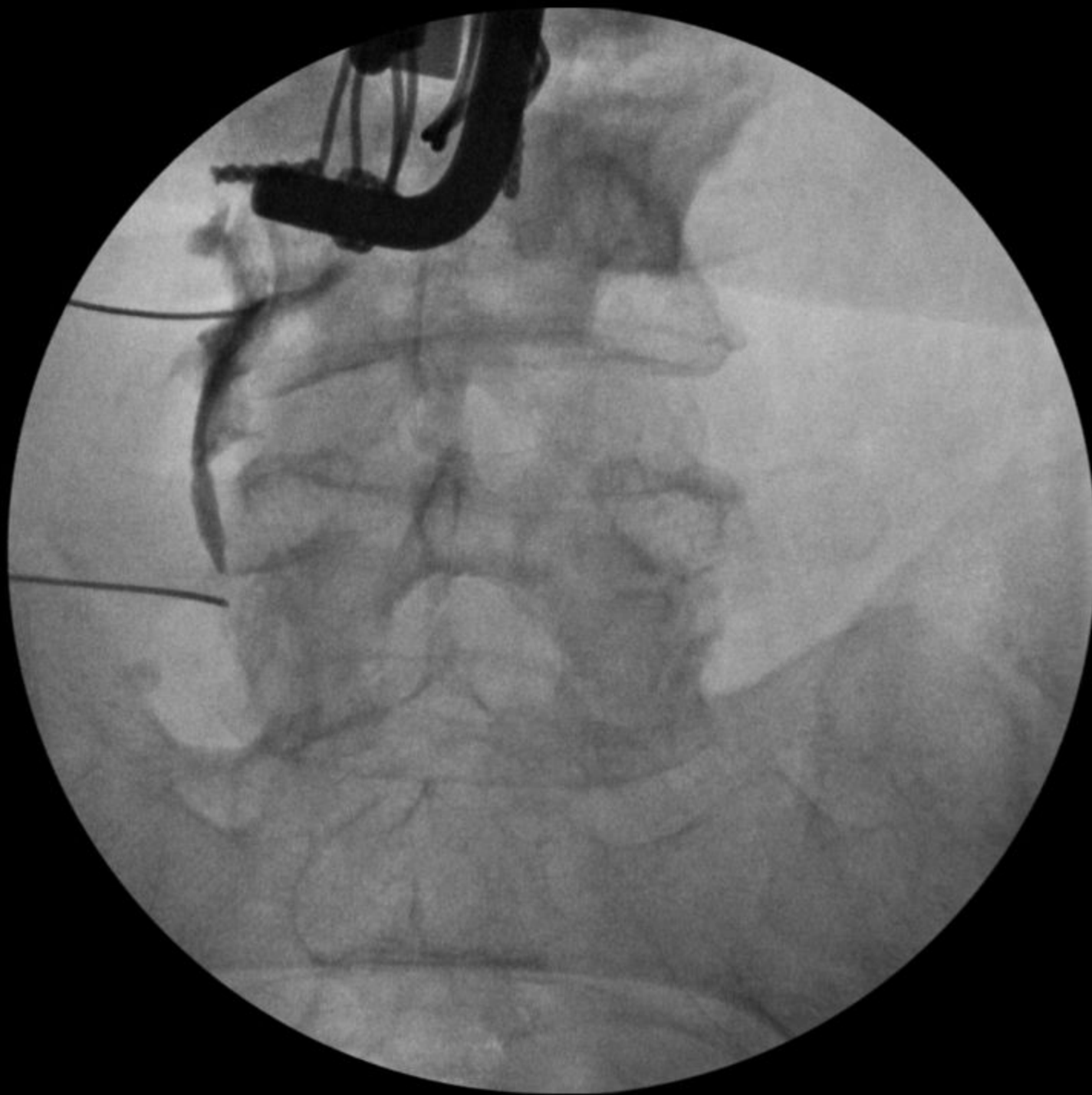


A

T-SPINE SGL
CTUH07


FOV: 350
512x512
2 @ -10 09060287

- ▶ 48 year old woman with a L2 ASIA B spinal cord injury from a motor vehicle accident with progressive left leg pain with activity



- ▶ Shoulder Pain
- ▶ Wrist/hand Pain
- ▶ Injuries
- ▶ Treatments that might impact MSK function
 - ▶ Steroids for asthma, rheumatological conditions
 - ▶ Statins

CHANGES IN MUSCULOSKELETAL FUNCTION

- ▶ 57 year old T6 ASIA spinal cord injury 20 years previously
 - ▶ Presents with right shoulder pain and weakness after a near fall during a transfer when her wheelchair brake malfunctioned
- 
- A decorative graphic consisting of several parallel white lines of varying lengths, slanted upwards from left to right, located in the bottom right corner of the slide.

017783749
F 02-Sep-49
07-Oct-14 6:46:46 PM
21904

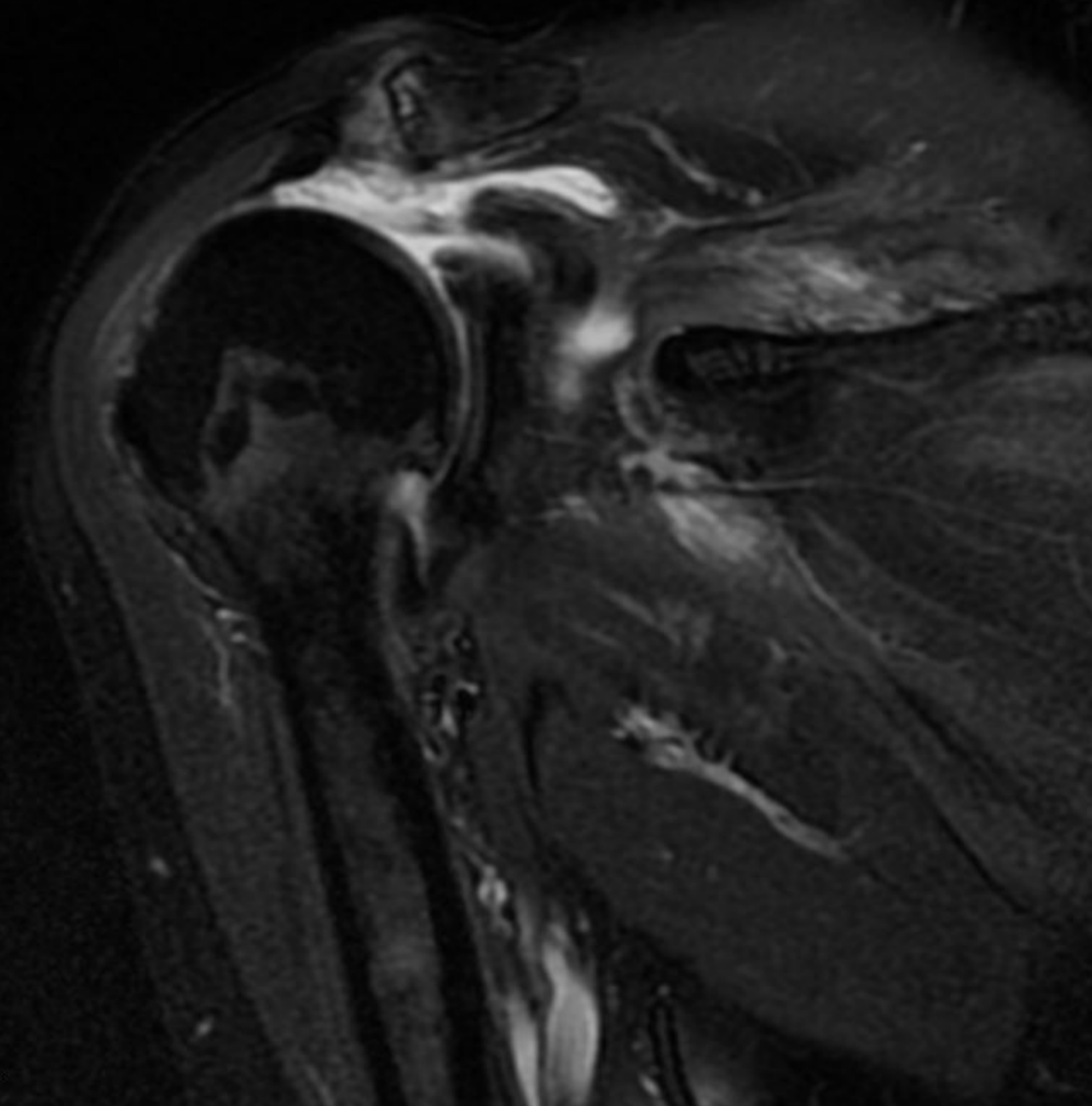
2D SE FAST_GEMS\FC_FREQ_AX_GEMS\FC\SAT_GEMS\NPWTRF_GEMS\FILTERED_GEMS\SP\FS
07-Oct-14 6:46:46 PM
TR:3166 TE:71.792

10 cm

AL

COR T2 FSE F/S
MRI UPR LFT EXTREM JNT WO CONTRAST-L
MR04EC

FOV: 160
HFS 512x512
3 @ -132 1996002



- ▶ Modifiable: Tobacco use, weight, hyperlipidemia, hypertension, hyperglycemia
- ▶ Increased risk of metabolic syndrome and CAD
 - ▶ Elevated homocysteine levels: associated with vascular disease
 - ▶ Elevated C-reactive protein levels: atherogenesis
 - ▶ Greater atherosclerotic burden
- ▶ Changes in heart chamber structure and function
 - ▶ Impacted by alterations in autonomic control
 - ▶ Impacted by lower peak exercise potential

CARDIOVASCULAR DISEASE

- ▶ LIPID PANEL
- ▶ THYROID STIMULATING HORMONE
- ▶ HgbA1C
- ▶ Testosterone

METABOLIC SYNDROME RISK AND MONITORING

- ▶ Impact of neuromuscular respiratory failure
 - ▶ Age related loss of volume and flow
- ▶ Impact of expiratory function loss
 - ▶ Neurological levels T6 and above
- ▶ Infection Risk
 - ▶ Pneumovax
 - ▶ Flu vaccination
- ▶ Impact of sleep disordered breathing
 - ▶ Incidence in cervical SCI 60%, up to 1/3 have central apnea as well
 - ▶ Incidence in thoracic SCI 20%
 - ▶ Incidence present at the time of injury (stable over the first year)

RESPIRATORY FUNCTION

- ▶ Spirometry with aging
- ▶ Sleep apnea testing
 - ▶ polysomnography
 - ▶ nocturnal trans-cutaneous oxygen and carbon dioxide measurements
- ▶ Treatment for expiratory dysfunction
 - ▶ Assisted cough
 - ▶ Cough assist machine (insufflator-exsufflator)
 - ▶ Mechanical secretion mobilization
 - ▶ Chest PT
 - ▶ Vibration
 - ▶ Vest

RESPIRATORY FUNCTION RECOMMENDATIONS

- ▶ Obstructive
 - ▶ Create clearance past area of proximal obstruction
 - ▶ Positive pressure
- ▶ Central
 - ▶ Address hypoventilation, which is not possible with pressure alone
 - ▶ Must have a back up rate to account for hypoventilation

OBSTRUCTIVE VS. CENTRAL APNEA TREATMENT

42 year old

- ▶ 8/24/17 developed neck and upper back tingling radiating down the LUE after turning left
- ▶ 8/25 difficulty climbing stairs
- ▶ 8/26 worsening weakness and SOB
- ▶ Admitted and intubated
- ▶ MRI: T2 hyperintensity at C1-5

	Actual	Predicted	%
FVC	1.92	5.07	38
FEV1	1.09	3.84	28
FEFMAX	1.14	9.29	12
FIFMAX	0.96	9.29	10

**EMG: NO DIAPHRAGM FUNCTION
ON LEFT**

- ▶ Yearly serum creatinine as a proxy for renal function
- ▶ Screening renal ultrasound for hydronephrosis
- ▶ Urodynamics to evaluate for bladder compliance and resultant risk to renal function
- ▶ Monitor frequency of urinary tract infections
 - ▶ Proxy for detrusor sphincter dyssynergia
 - ▶ Proxy for renal/bladder stones
 - ▶ Indwelling catheter
 - ▶ ISC/CIC technique
- ▶ Bladder cancer monitoring with cystoscopy

RENAL FUNCTION MONITORING

- ▶ Vitamin D monitoring
- ▶ Monitor calcium consumption and supplement as needed
- ▶ Bone density monitoring: baseline and every five years
- ▶ What we know about weight bearing benefits and risk is very limited

BONE HEALTH

- ▶ Biphosphonates
 - ▶ Inhibit osteoclast activity by blocking the farnesyl diphosphate synthase in the mevalonate pathway.
- ▶ Selective estrogen receptor modulator (SERM)
 - ▶ Raloxifene
- ▶ IgG2 monoclonal antibody with affinity and specificity for human RANKL (receptor activator of nuclear factor kappa-B ligand)
 - ▶ Denosumab
- ▶ Statins
 - ▶ Inhibit osteoclastic activity by way of the mevalonate pathway by blocking HMG-CoA reductase

BONE HEALTH TREATMENT

- ▶ Increased risk in patients taking medications that negatively impact saliva production
 - ▶ Anti-cholinergic
- ▶ Increased risk in patients with tube feeding and reflux
- ▶ Increased risk in patients on ventilator

DENTAL EXAMINATION



QUESTIONS?

